

ON THE PATHOGENESIS OF THE HEPATIC AND RENAL LESIONS IN LEPTOSPIROSIS

Thales de BRITO

SUMMARY

The pathogenesis of the hepatic and renal lesions both in human and experimental leptospirosis is briefly discussed.

Previous bacteriologic and experimental pathology work are highly suggestive of a toxin or toxins as the main mechanisms in leptospiral pathogenicity. Such a toxin could act on capillaries, in hepatic and in tubular cells of the kidney. Lesions could be the result either of a direct action of the circulating toxin or toxins or of the diminished oxygen supply to the cells because of the capillary damage.

The mechanism of icterus in leptospirosis is also discussed in the light of the ultrastructural findings and a correlation between morphology and the altered bile metabolism was attempted.

INTRODUCTION

Since 1963 we have been studying the hepatic and renal aspects of human leptospirosis. Most of our work is based on kidney and liver biopsies and our experience has suggested that this procedure is relatively innocuous, provided that maximum care is used and proper consideration be given to the occurrence of obvious complications¹¹.

Previous work of AREAN² and, more recently, of SEFER¹³ pointed out a toxin, probably an endotoxin, as the main mechanism of action in leptospiral pathogenicity.

This toxin appears to act on capillaries as evidenced by a swollen endothelium and increased permeability. Hemorrhage and interstitial edema are prominent features. This vascular pathology explains the reddish-yellow jaundice which may be the result of the biliary pigmentation plus vascular dilation and/or hemorrhage. Certain aspects of the disease such as the hemorrhagic pneumonia

could be also explained by the capillary damage.

The liver is enlarged and usually shows at post mortem examination a lack of trabecular arrangement of the hepatic cells. This is also seen in the terminal phase of the experimental leptospirosis^{1, 6} but is absent in ante mortem liver biopsies of human leptospirosis^{3, 7, 10}. This loss of architecture seen only at necropsy may appear in the more acute phase of the disease or during the agonal period.

The mechanism of icterus in leptospirosis remain unexplained. Light microscopy of the biopsied liver³ discloses cholestasis. The ultrastructural study shows normal hepatic cells side by side with cells showing altered sinusoidal pole microvilli and evidence of mitochondrial injury^{3, 12}. Kupffer cells are hyperplastic and hypertrophic, with many autophagic vacuoles. This sinusoidal alteration could be the result of the action of a circulat-

This work was partially supported by a grant of the IBEPEGE Pathologist, "Instituto de Medicina Tropical de São Paulo" (Universidade de São Paulo) and "Hospital Emílio Ribas", São Paulo, Brasil

ing toxin or toxins. Also, the altered sinusoidal pole could help in explaining a lack of absorption of unconjugated bilirubin and its increased serum levels. However, it should be pointed out that a slight degree of hemolysis is also present, as demonstrated by the presence of a few hemosiderin granules in Kupffer cells³.

Electron microscopy also disclosed definite

alterations of the bile canaliculi microvilli, which is a non specific finding usually linked to a deficit of bile excretion. Moreover, the hepatic cells showed altered mitochondria, and ribonuclein and glycogen granules depletion. Probably the bile conjugation and transport mechanisms are also damaged in human leptospirosis, possibly as a result of the same toxin or toxins.

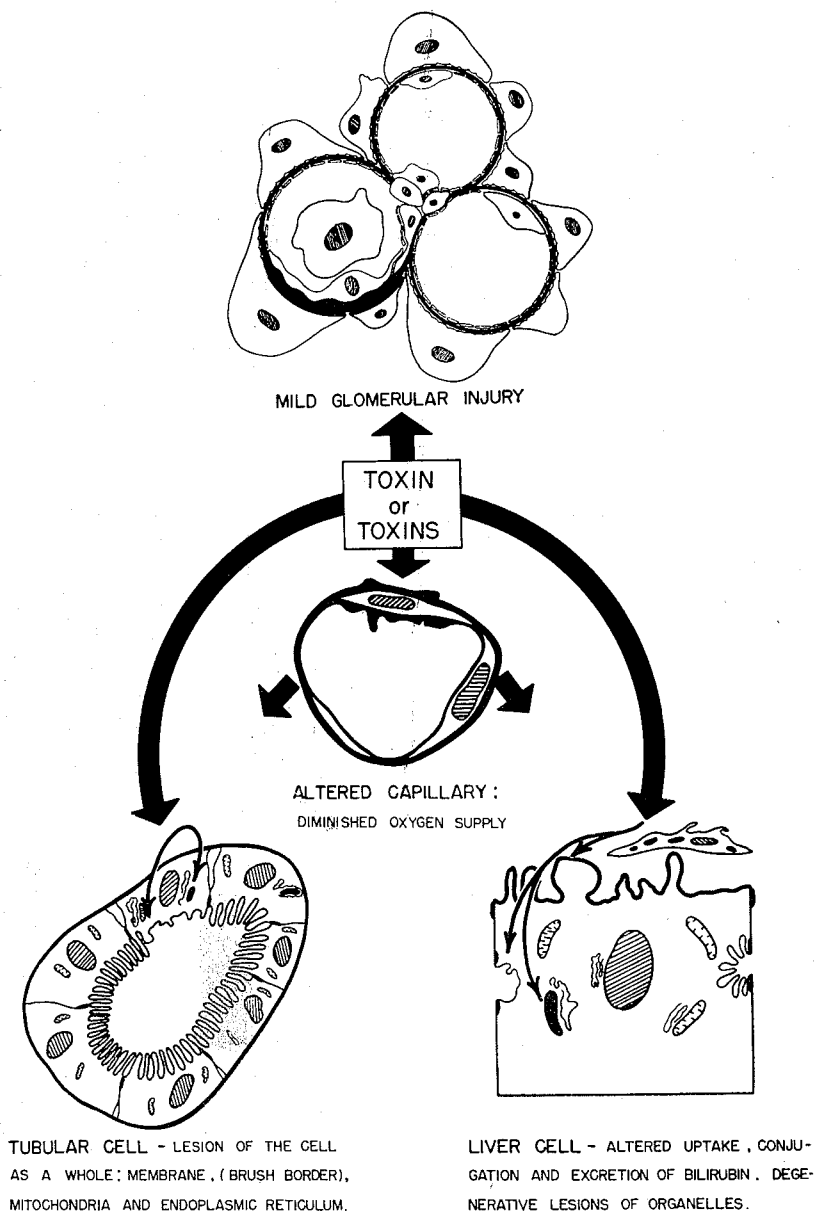


Fig. 1 — Schematic representation of the pathogenesis of leptospirosis

If a correlation between ultrastructural changes and bile pigment metabolism could be attempted, we might say that such metabolism is disturbed in uptake (sinusoidal pole injury), conjugation (ribonuclein granules depletion) and excretion (mitochondrial and biliary ductules pathology), with a predominance of the last phase. It is worth emphasizing that biochemical changes in leptospirosis are not suggestive of a marked cellular necrosis. Transaminase levels are not remarkably increased (generally below 500 Sigma-Fraenkel units) and α -globulins and mucoproteins are elevated^{8,9}.

The kidney lesions are both of an interstitial nephritis and a focal acute tubular damage. Injured nephrons are seen alternating with normal ones, without a definite pattern of distribution. Furthermore, in the former, damaged cells are seen throughout the entire nephron, side by side with normal ones⁴.

Proximal and distal tubules may appear dilated and casts are seen in the lumina of the latter¹¹. Interstitial edema is prominent, chiefly at the cortico-medullary junction, where a chronic inflammatory infiltrate is also seen. However, areas of focal interstitial nephritis, made up of lymphocytes, histiocytes and few eosinophils can be seen in the cortex, sometimes around glomeruli. Electron microscopy disclosed cells of the proximal tubules with altered brush border and mitochondria, and a predominance of the smooth type of reticulum^{4,5}. Biochemical study of succinodehydrogenase, alkaline and acid phosphatase, done in kidney biopsies revealed a decreased enzymatic activity⁴. Those findings pointed to an injury of the tubular cell as a whole.

A limited number of glomeruli exhibited mild lesions which explains, at least partially, the proteinuria seen in the disease⁵. Glomerular capillary loops showed mild and focal endothelial swelling and epithelial cells occasionally appeared with their foot process fused. The internal lamina rara is irregular, edematous, probably as a result of the action of the so far hypothetical toxin or toxins. In some of the glomerular capillary loops inflammatory cells can be seen obstructing their lumina⁴.

The tubular lesions can be the result either of the action of a toxin filtered

through the glomeruli and having its effect enhanced by tubular concentration or of the diminished oxygen supply due to the capillary pathology. Probably both mechanisms play a role in the pathogenesis of the kidney failure which is regarded as the main cause of death both in human and experimental leptospirosis (Fig. 1).

RESUMO

Patogênese das lesões hepáticas e renais na leptospirose

Os trabalhos bacteriológicos e de patologia experimental sugerem que uma toxina ou toxinas são produzidas pela leptospira, sendo os elementos fundamentais para a compreensão do mecanismo patogênético da doença. Esta toxina ou toxinas circulantes agiriam ou diretamente na célula hepática e do túbulo renal ou através do dano capilar, o qual determinaria para elas deficiente suprimento de oxigênio.

O mecanismo da icterícia na leptospirose também foi discutido e foi tentada correlação entre achados morfológicos pela microscopia óptica e eletrônica e o metabolismo alterado da bile.

REFERENCES

1. AREAN, V. M. — Studies on the pathogenesis of leptospirosis. II — A clinico-pathologic evaluation of hepatic and renal function in experimental leptospiral infections. *Lab. Invest.* 11:273-288, 1962.
2. AREAN, V. M.; SARASIN, G. & GREEN, J. H. — The pathogenesis of leptospirosis: toxin production by *Leptospira icterohaemorrhagiae*. *Amer. J. Vet. Res.* 25:727-738, 1964.
3. BRITO, T.; MARCONDES MACHADO, M.; MONTANS, S. O.; HOSHINO, S. & FREY-MÜLLER, E. — Liver biopsy in human leptospirosis: a light and electron microscopy study. *Virchow. Arch. Path. Anat.* 342:61-69, 1967.
4. BRITO, T.; PENNA, D. O.; PEREIRA, V. C. & HOSHINO, S. — Kidney biopsies in human leptospirosis: a biochemical and electron microscopy study. *Virchow. Arch. Path. Anat.* 343:124-135, 1967.

5. BRITO, T.; PENNA, D. O.; SANTOS, H. S.; FREYMÜLLER, E.; SOARES DE ALMEIDA, S.; AYROSA GALVÃO, P. A. & PEREIRA, V. — Electron microscopy of human leptospirosis (kidney biopsies). *Amer. J. Trop. Med.* 14:397-403, 1965.
6. BRITO, T.; FREYMÜLLER, E.; HOSHINO, S. & PENNA, D. O. — Pathology of the kidney and liver in the experimental leptospirosis of the guinea-pig: a light and electron microscopy study. *Virchow. Arch. Path. Anat.* 341:64-78, 1966.
7. DOTTI, F. & SABBIONI, G. — Il quadro istomorfológico del fegato nelle leptospirose benigna: studio biotico con particolare riguardo alle forme anicteriche. *Arch. Pat. Clin. Med.* 36:81-101, 1959.
8. ELKIS, H.; ROSENBOJM, J.; KURBAN, S.; AMATO NETO, V.; KUSMINKY, N.; FURTADO, M. R. & MEIRA, J. A. — I — Valor da determinação da mucoproteína sérica no diagnóstico diferencial das ictercias. *Rev. Hosp. Clin. Fac. Med. São Paulo* 14:446-459, 1959.
9. ELKIS, H.; AMATO NETO, V. & MEIRA, J. A. — II — Transaminase glutâmico-oxalacética no soro de pacientes com leptospirose. *Rev. Inst. Med. trop. São Paulo* 4: 217-219, 1962.
10. OSTERTAG, H. — Leptospirosis icterohaemorrhagica in Bulgarien. *Z. Hyg. Infektionskr.* 131:482-500, 1950.
11. PENNA, D. O.; BRITO, T.; AGUIAR PUPO, A.; MARCONDES MACHADO, M.; AYROSA GALVÃO, P. A. & ALMEIDA, S. S. — Kidney biopsy in human leptospirosis. *Amer. J. Trop. Med.* 12:896-901, 1963.
12. SANDBORN, E. B.; CÔTÉ, M. G. & VIALLET, A. — Electron microscopy of a human liver in Weil's disease (Leptospirosis icterohaemorrhagica). *J. Path. Bact.* 92:369-374, 1966.
13. SEFER, M. — Über antigenstruktur und endotoxine der Leptospiren. *Ann. Soc. Belg. Med. Trop.* 46:259-266, 1966.

Recebido para publicação em 11/1/1968.