

HUMAN SPOROTRICHOSIS FOLLOWING RAT BITE

Olga FISCHMAN (1), Maurício M. A. ALCHORNE (2) and M. A. S. C. PORTUGAL (3)

SUMMARY

A human case of sporotrichosis following the bite of a rat is described. Attempts were made to isolate *Sporothrix schenckii* from the mucosa of the oral cavity of 50 albino rats. Intradermoreaction with Sporotrichin was performed in these laboratory animals. Results were all negative. Attention is called to the role of animals which act as carriers of *S. schenckii*.

INTRODUCTION

Human and animal sporotrichosis in Brazil were first described by LUTZ & SPLENDORE⁶. Clinical manifestations, etiology and mycology of the disease have been studied all over the world. The mycosis is commonly associated with injury by plants, timber, metal pieces or, in less instances, animal bites.

The present report describes a case of sporotrichosis in a boy, following rat bite, seen in São Paulo (Brazil).

MATERIAL AND METHODS

Case report — M.C.S., ten years old, male, Caucasian, student, lives at Diadema (São Paulo, Brazil). He was seen for diagnosis and treatment at the "Disciplina de Dermatologia da Escola Paulista de Medicina", in July, 1971. At that time he presented an ulcer-like lesion, on the nasal region, 2 cm in diameter, partially covered by sero-purulent crusts, infiltrated at its base and surrounded by small reddish nodules (Fig. 1).

A rat had been seen scuttling from the boy's bed; soon after, the boy showed visible signs of the animal bite in his face, and 15 days later an inflammatory lesion developed at the nasal region. When seen by us, the patient had already been submitted to antibioticotherapy, with no result.

Mycology — Samples of material from the lesion were submitted to direct microscopic examination, and cultivated on Mycosel agar (BBL). The identification of the isolate was confirmed by inoculation of 0.2 ml of saline cell suspension from filamentous culture, by intratesticular route, in both tests of a rat.

Investigation on natural infection of laboratory rats — According to the studies of LUTZ & SPLENDORE⁶, MEYER,⁸ MOORE & DAVIS¹⁰, JEANSELME & CHEVALLIER (in MOORE & DAVIS)¹⁰ and our own observations, we tried to isolate *Sporothrix schenckii* from the mouth cavity of 50 healthy albino rats. Intradermoreaction with 0.1 ml of 1/1000 diluted Sporotrichin antigen (received from Dr. Schneidau, Tulane University) was performed in these laboratory animals, in order to disclose a possible sporotrichosis infection.

RESULTS

Direct microscopic examination of the exudate and pus from the lesions did not disclose the presence of any fungal elements. Concerning the cultures, on the third day, fungal colonies had developed in all tubes, cream-like in color and with short aerial mycelium. Microscopical examination revealed the classical features of "in vitro" cultures of *S. schenckii*.

Supported in part by Fundação de Amparo à Pesquisa do Estado de São Paulo, São Paulo, Brasil

(1) Departamento de Microbiologia e Parasitologia, Escola Paulista de Medicina, Rua Botucatu 862, São Paulo, Brasil

(2) Disciplina de Dermatologia, Escola Paulista de Medicina

(3) Médico-Veterinário, Instituto Biológico, Bolsista do CNPq, São Paulo, Brasil

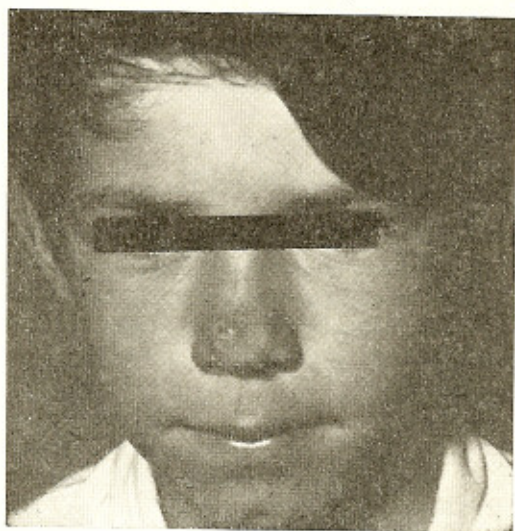


Fig. 1 — An ulcer-like lesion on the nasal region of the boy

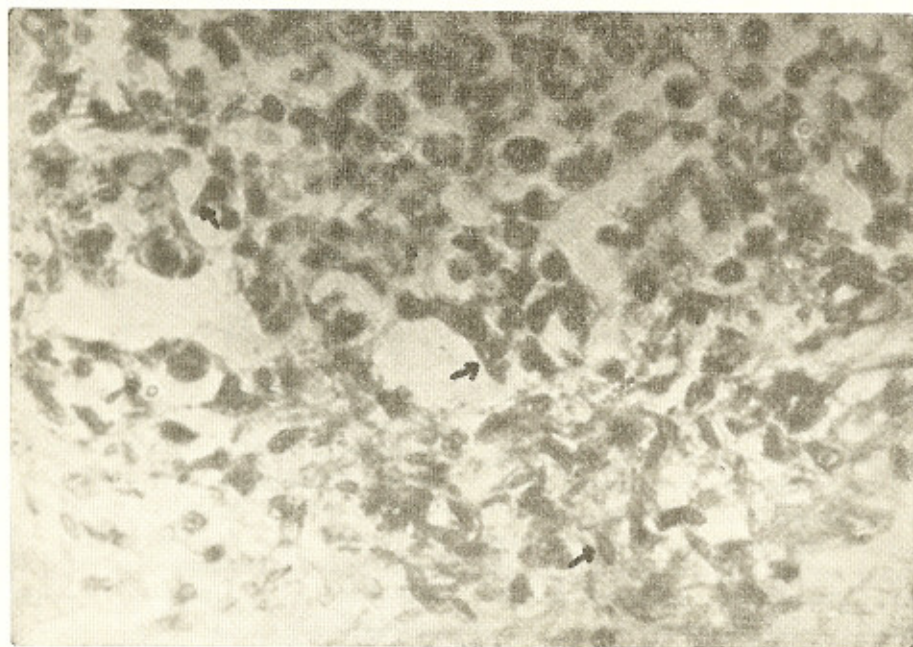


Fig. 2 — Tissue section from inoculated rat, showing cigar-shaped structures, PAS stain, 700 x

As for the animal inoculation, after 12 days the animal was killed and presented bilateral orchitis with swelling of both tests, which were hard to the touch and adherent to the external wall of the scrotum. Tissue sections from experimentally infected rat, with PAS stain, showed round and "cigar-shaped" structures which varied in size, in the intertubular conjunctive tissue, inside the giant cells and also in the granulomae (Fig. 2) *S. schenckii* was recovered in pure cultures on Mycosel agar from orchitis pus.

The 50 healthy albino rats examined were neither positive for *S. schenckii* nor for the Sporotrichin test.

The patient was partially healed, 40 days after the beginning of treatment with 2 g/day potassium iodine.

COMMENTS

In Brazil, human sporotrichosis is the most frequent systemic mycosis^{4, 13, 15}. The cases reported in statistics must be below the real number, because the disease is in most cases of easy diagnosis and treatment, and the patients are not led to a specialized service.

In Brazil, animal sporotrichosis has been described in rats⁶, asinines^{7, 11}, mules^{3, 12, 14}, dogs^{2, 5, 9, 16} and cats^{1, 2}.

LUTZ & SPENDORE⁸ described sporotrichosis in 40 naturally infected albino rats and confirmed their former observation in wild gray rats. They studied the human mycosis and the disease in spontaneously and experimentally sick animals. They have isolated *S. schenckii* from the oral mucosa of rats and called attention to the transmission of sporotrichosis by rat bite.

Rats, living in close contact and feeding on plant debris where the fungus often vegetates in nature, may in some way act as carriers of *S. schenckii*.

MEYER⁸ has isolated *S. schenckii* from the mouth cavity of an apparently healthy horse and emphasizes the role of normal animals acting as passive carriers of *Sporothrix*. He correlates cases of human to animal sporotrichosis.

MOORE & DAVIS¹⁰ studied a case of sporotrichosis in a boy after a bite on his index finger, by a field mouse.

JEANSELME & CHEVALLIER (in MOORE & DAVIS)¹⁰ reported an interesting sporotrichosis case in a woman following the bite on the thumb, by a white rat. This rat had been experimentally infected with *S. schenckii*.

The case presently reported represents one more instance of such circumstantial infection; however, we do agree with MOORE & DAVIS¹⁰ who have called attention to the fact that in none of the human sporotrichosis cases following animal bite reported in literature, it can be stated that the fungus was carried into the lesion by the teeth or that it was present in the mouth of the animal; it may also have been on the skin of the patient or may have later found its way into the wound, the bite serving simply as a means of entry.

RESUMO

Esporotricose humana após mordedura por rato

É descrito um caso de esporotricose humana, na região nasal de um paciente, após mordedura por rato.

Fizeram-se tentativas para isolamento de *S. schenckii* da mucosa bucal de 50 ratos de laboratório. Intradermo-reação com esporotriquina foi experimentada, nesses animais, para surpreender esporotricose infecção. Os resultados foram todos negativos.

Chama-se atenção para a ocorrência da esporotricose por mordedura de animais.

ACKNOWLEDGEMENT

Our thanks to Dr. R. M. Saliba (Adjunct Professor of Pathological Anatomy) for the histopathologic interpretation of the section slides.

REFERENCES

1. FREITAS, D. C.; MIGLIANO, M. F. & ZANI NETO, L. — Esporotricose. Observação de caso espontâneo em gato doméstico (*F. catus*, L.). *Rev. Fac. Med. Vet. Univ. São Paulo* 5:601-604, 1956.
2. FREITAS, D. C.; MORENO, G.; BOTINNO, J. A.; MOS, E. N. & SALIBA, A. M. — Esporotricose em cães e gatos. *Rev. Fac. Med. Vet. Univ. São Paulo* 7:381-387, 1965.

3. LEAO, A. E. A.; SILVA, J. O. & PROENÇA, M. — Sur un cas de sporotrichose à *Sporotrichum beurmanni*. *Bol. Vet. Exerc.* (Rio de Janeiro) 2:45-49, 1935.
4. LONDERO, A. T. — Alguns aspectos das micoses no interior do Rio Grande do Sul. *Rev. Fac. Farm. Santa Maria* 12:63-70, 1966.
5. LONDERO, A. T.; CASTRO, R. M. & FISCHMAN, O. — Two cases of sporotrichosis in dogs in Brazil. *Sabouraudia* 3:273-274, 1964.
6. LUTZ, A. & SPLENDORE, A. — Sobre uma mycose observada em homem e ratos. *Rev. Med. São Paulo* 21:433-450, 1907.
7. MELLO, A. — Um caso de esporotricose verrucóide. *Rev. Ind. Anim.* 1:305-309, 1935.
8. MEYER, K. F. — The relation of animal to human sporotrichosis. *J. Amer. Med. Ass.* 65:579-585, 1915.
9. MIGLIANO, M. F.; FREITAS, D. C. & MORENO, F. — Esporotricose em cães. *Rev. Fac. Med. Vet. Univ. São Paulo* 7:225-233, 1963-1964.
10. MOORE, J. J. & DAVIS, D. J. — Sporotrichosis following mouse bite with certain immunologic data. *J. Infect. Dis.* 23:252-265, 1918.
11. MOREIRA, E. C.; KASSAI, Y. & BARBOSA, M. — Esporotricose em asinino no Estado de Minas Gerais. *Arq. Esc. Vet.* (Minas Gerais) 19:189-191, 1967.
12. PIRATININGA, N. N. — Esporotricose em muar. *Rev. Fac. Med. Vet. Univ. São Paulo* 2:219-222, 1943.
13. ROTBERG, A.; DEFINA, A. F. & PEREIRA, C. A. — Dados sobre a frequência das micoses profundas em especial da esporotricose na clínica dermatológica da Escola Paulista de Medicina (1951-1960). *Rev. Fac. Med. Univ. Ceará* (Brasil) 3:84-88, 1963.
14. SALIBA, A. M.; SORENSEN, B. & VEIGA, M. J. S. — Esporotricose em muar. *O Biológico* 29:209-212, 1963.
15. SILVA, D. & NAZARÉ, J. P. — Casos de esporotricose no Pará (Observação em 5 anos 1962/1966). *An. Bras. Dermatol.* 41:219-220, 1966.
16. SOUZA, J. S. — Esporotricose em cão. *An. VII Cong. Brasil. Vet. Recife* 1:367-370, 1957.

Recebido para publicação em 13/7/1972.